



Multiple Choledochan Litisison of a Case Presentation

Dr. Yosniel Lugo Echevarría¹, Dra. Anaisa León Mursull², Dr. Pedro Rolando López Rodríguez³

^{1,3}General Teaching Hospital "Dr. Enrique Cabrera", Havana

²Stomatology Clinic, Havana

Received: 01.11.2024 | Accepted: 03.11.2024 | Published: 10.12.2024

*Corresponding Author: Dr. Pedro Rolando López Rodríguez³

Abstract	Case Studies
<p>Introduction: Choledocholithiasis is the most common cause of bile duct obstruction, occurring in 10-20% of patients with cholecystolithiasis, 7-14% of patients with cholecystectomy, and 18-33% of patients with acute biliary pancreatitis. Objective: To present a case with a giant multiple choledocholithiasis, with good evolution.</p> <p>Clinical Table: Female patient of 57 years of age, mixed race, smoker, hypertensive, with a history of vesicular lithiasis that was operated 28 years ago where initially it is treated by videolaparoscopy but in the transoperative it is determined its conversion to conventional cholecystectomy. The same goes to consultation of the area because it begins with pain in the epigastrium, dyspepsia, urine dark urine and sometimes gray stool for which they indicate a study and assess by the services of gastroenterology, general surgery where the surgical intervention is decided. Initially treated by ERCP and subsequently performed a Choledocholithotomy with placement of Kerh probe.</p> <p>Conclusions: The patient showed a favorable evolution.</p> <p>Keywords: Lithiasis Choledocyan, Choledocholithiasis, Choledochotomy</p>	

INTRODUCTION

Choledocholithiasis is the most common cause of bile duct obstruction, occurring in 10-20% of patients with cholecystolithiasis, in 7-14% of patients who underwent cholecystectomy, and in 18 -33% of patients with acute gallstone pancreatitis. Although this disease may be asymptomatic, it is associated with increased morbidity and mortality due to the development of other diseases such as acute gallstone pancreatitis or acute ascending colangitis 1. Choledocholithiasis can have special presentations; this contributes to the fact that the treatments (endoscopic and surgical) are difficult and can present complications or require several procedures for their resolution, increasing morbidity2. The first therapeutic option for choledocholithiasis associated with gallstones is transcystic instrumentation (TCI). In case of failure, a choledochotomy is performed, followed by primary common bile duct closure (CPC), T-tube placement, or biliodigestive bypass. Currently the CPC is the most accepted option; however, it can present complications, among them bile leakage is the most frequent 2.3

Case Presentation

A 57-year-old female patient, mixed-race, smoker, hypertensive, with a history of gallbladder lithiasis who underwent surgery 28 years ago, initially trying to approach it by videolaparoscopy, but during the intraoperative period, conversion to conventional cholecystectomy was determined. She herself goes to the area's consultation because she begins with pain in the epigastrium, dyspepsia, dark urine and sometimes gray feces for which a study is indicated and evaluated by the gastroenterology and general surgery services. While waiting for the evaluations, she has an episode of intense pain in the right hypochondrium, nausea, vomiting, chills and general seizure. Days later she is treated in the emergency department at the hospital to which she corresponds by her municipality and she is

diagnosed with icteric syndrome where an analysis with an abdominal ultrasound is urgently indicated, which reports the absence of a gallbladder but the presence of dilation of the intrahepatic bile duct. and extrahepatic with a common bile duct diameter of 18 mm, for which reason surgery was consulted to rule out the acute emergency entity and admission was taken as the procedure to conclude the study and prepare for possible endoscopic treatment in a specialized tertiary care center (ERCP). .Once the preoperative check-up is ready, it is evaluated by anesthesia and an ERCP is indicated, which was diagnostic and therapeutic, informing us that the patient has a multiple lithiasis of the primary distal common bile duct to which a wide sphincterotomy is performed with endoprosthesis placement. of 18 french with previous extraction maneuvers of the same one not being effective for what is suggested traditional surgical treatment of the extrahepatic bile duct for the performance of choledolithotomy. Once re-evaluated by our service and by the anesthesiology service, the patient's surgery is scheduled on 02/15/2023, confirming the referred preoperative diagnosis where opening, extraction, washing, and permeabilization of the GBV are made. The endoprosthesis was removed and a T-tube was placed by misadventure. On the seventh day, percutaneous cholangiography was performed through the T-tube.

Figure No.1 Common bile duct dilation

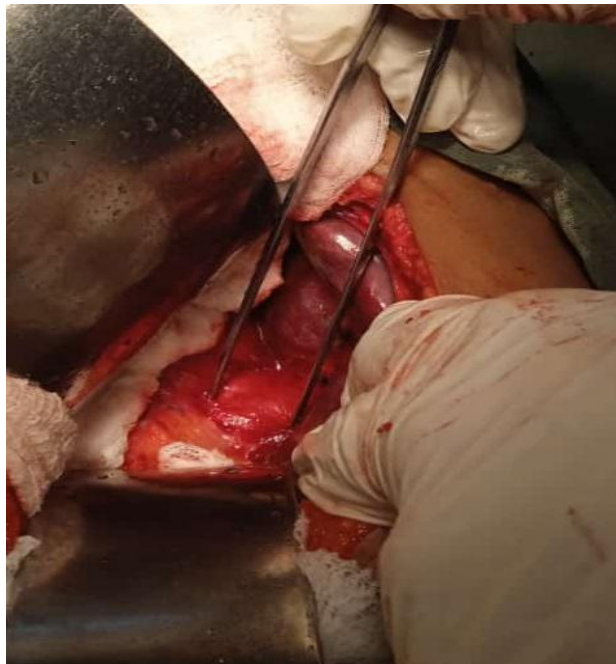

Figure No.2. Choledocholithotomy with Randall clamp

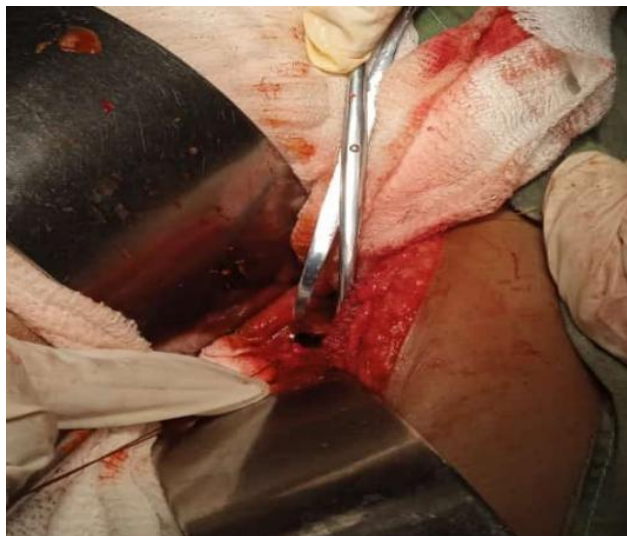


Figure No.3. Extraction of the bioprosthesis

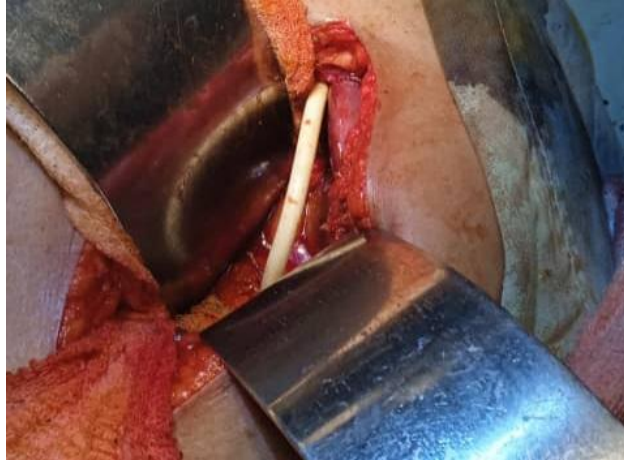

Figure No. 4 Biliary prosthesis and multiple extracted stones



DISCUSSION

The incidence of asymptomatic PVB lithiasis diagnosed in patients referred for laparoscopic cholecystectomy has been established at around 10%². When choledocholithiasis is identified in patients who still have a gallbladder, passage of the stones through the cystic duct into the GBV is assumed and, in principle, all stones are considered secondary to migration. However, choledocholithiasis also develops in patients long after having undergone cholecystectomy. A recent study showed a median of 4 years for the onset of symptomatic choledocholithiasis in patients undergoing cholecystectomy⁴. The time period until choledocholithiasis recurrence after any GBV clearance procedure is not very different, ranging from 1.4 to 4 years depending on studies⁵. Since it is difficult to accurately distinguish between migrated stones that were left in situ during surgery and stones that formed de novo in the VBP after surgery, most studies performed a classification arbitrary list of retained and recurrent lithiasis according to the moment of appearance from the last therapeutic procedure. The norm of 6 months, 12 months or even two years has been widely used to define recurrent choledocholithiasis⁶. Like many other authors, we use the time of 6 months to define recurrent lithiasis. This may have contributed to a slightly higher recurrence rate compared to the few studies that highlight this problem.

There are mainly two mechanisms by which a lithiasis inadvertently remains in the bile duct after any therapeutic approach. First, the presence of lithiasis in the cystic duct that can migrate towards the GBV after the surgical procedure. Despite milking the cystic duct into the gallbladder during laparoscopic cholecystectomy, some stones may persist. Complete clearance of the cystic may be difficult to ensure during transcholedochal choledochoscopy, and furthermore, balloon removal of choledocholithiasis during the endoscopic or

surgical approach may introduce stones from the GBV into the cystic duct. Secondly, a false negative in cholangiographic or fibro-choledochoscopic examinations can also cause the persistence of choledocholithiasis after surgery. In the opinion of the authors, these mechanisms of failure in the removal of GBV stones may be responsible for the early cases of recurrence and, therefore, should be better declared as retained lithiasis, but they can hardly cause symptomatic choledocholithiasis after 6 months or many years later. The true incidence of retained or recurrent stones is always difficult to ascertain. Due to the retrospective nature of our study, some cases of asymptomatic choledocholithiasis may not have been diagnosed, particularly assuming spontaneous clearance of GBV stones in 12-26% of affected patients^{7,8,9,10}. Most of the studies that compare the endoscopic and surgical approach for the management of choledocholithiasis do not stratify the therapeutic approach based on age and few of them analyze the long-term results to determine the recurrence of lithiasis. Whether an endoscopic sphincterotomy that facilitates bile duct emptying, even causing permanent bile reflux, might be a better treatment option than surgical stone removal in elderly patients to prevent recurrence should be investigated.

CONCLUSIONS

The ideal management of bile duct stones remains controversial. Deciding on endoscopic, laparoscopic, or conventional management of bile duct lithiasis requires adequate logistics, institution, training, and clinical judgment. Due to the great variety of elements involved in decision making, each case must be analyzed individually. Our patient showed a favorable evolution. Conflict of interest. The authors declare that they have no conflict of interest.

REFERENCES

1. C. Ovalle-Chao, D.A. Guajardo-Nieto, R.A. Elizondo-Pereo, Performance of the predictive criteria of the American Society for Gastrointestinal Endoscopy in the diagnosis of choledocholithiasis at a secondary care public hospital in the State of Nuevo León, Mexico, *Revista de Gastroenterología de México (English Edition)*, 2022, ISSN 2255-534X, <https://doi.org/10.1016/j.rgmexen.2022.06.005>.
(<https://www.sciencedirect.com/science/article/pii/S2255534X22000688>)
2. Petracchi Enrique, Quesada Bernabé M., Baglietto Nicolás, Merchán Pablo, du Plessis Cristina, Canullán Carlos. Innovación en técnica quirúrgica: Dos técnicas no convencionales para el tratamiento de la coledocolitiasis. *Rev. argent. cir.* [Internet]. 2022 Oct [citado 2023 Mar 07] ; 114(4): 348-354. Disponible en: http://www.scielo.org.ar/scielo.php?script=sci_arttext&pid=S2250-639X2022000400348&lng=es.
<http://dx.doi.org/10.25132/raac.v114.n4.1676>
3. Salom Andrés, Miranda Andrés, País Cecilia, Murias Federico, Giliberti Bruno, Abiuso Luciano et al . Incidencia de litiasis vesicular asintomática en pacientes con complicaciones biliares. *Cir. Urug.* [Internet]. 2022 Jul [citado 2023 Mar 07] ; 6(1): e202. Disponible en: http://www.scielo.edu.uy/scielo.php?script=sci_arttext&pid=S1688-12812022000101202&lng=es. Epub 01-Jul-2022. <https://doi.org/doi10.31837/cir.urug/6.1.12>
4. Parra-Membrives P, Martínez-Baenas D, Lorente-Herce JM, Jiménez Rivera G, Sánchez Galves MA. *Rev Esp Cir.* 2019; Vol 97 (6) : 336-342 . DOI: 10.1016/j.ciresp.2019.02.012
5. Beltrán Miranda P, Alba Valmorisco M, Marín Gómez LM, González Serna DB. *Rev Esp Cir.* 2019 ; Vol 97(10): 611-612 .
<https://doi.org/10.1016/j.ciresp.2019.07.002>
6. Devinares de Cardenas J, Revoredo Rego F. Litiasis del Hepatocolédoco .*Rev Argent Cir.* 2020 ; Vol 112 (4) .
<http://doi.org/10.25132/raac.v112.n4.ande>
7. Petroacchi E, Quesada BM, Baglietto N, Merchán P, De Plessis C, Camellán C. Innovación en técnica quirúrgica . Dos técnicas no convencionales para el tratamiento de la coledocolitiasis .*Rev Argent Cir* 2022; Vol 114 (4):348-354
<http://doi.org/10.25132/raac.v114.n4.1676>
8. Aleán Argueta LF, Ramírez Toncel SM, Cifuentes Sandoval SF, Izquierdo Gracia DF, Vergara Gómez JM. Complicaciones secundarias a coledocolitiasis y su manejo: Puntos fundamentales para el diagnóstico. *Rev Colomb Radiol* [Internet]. 2017 [citado 27 Feb 2022]; 28(3):4717-24. Disponible en: <http://contenido.acronline.org/Publicaciones/RCCR/RCCR28>

9. Morales Martínez I, Molina León O, Echavarría Fraga DR. Resultados en el diagnóstico y el tratamiento de la coledocolitiasis. Acta Méd Centro [Internet]. 2020 [citado 27 Feb 2021]; 14(1): [aprox.5p.]. Disponible en: <http://www.revactamedicacentro.sld.cu/index.php/amc/article/view/1112>
10. Toro Calle J, Guzmán Arango C, Ramírez Ceballos M, Guzmán Arango N. ¿Son los criterios de la ASGE suficientes para la estratificación del riesgo de coledocolitiasis?. Rev Colomb Gastrointest [Internet].2020 [citado 27 Feb 2021];35(3):304-310.Disponible en: <https://doi.org/10.22516/25007440.464>