



Inhalation of a Foreign Body when Using a Dosed Aerosol

Meridj A¹, Belala R², Tlili K³, Djeghri Y⁴

^{1,2,3,4} Pulmonology Service, Constantine Regional Military University Hospital, Algeria

Received: 01.11.2024 | **Accepted:** 03.11.2024 | **Published:** 24.11.2024

***Corresponding Author:** Meridj A¹

DOI: 10.5281/zenodo.14914305

Abstract		Case Report
<p>Asthmatics often use inhalation devices and many precautions are often neglected such as closing the nozzle after use.</p> <p>We report the observation of a 54-year-old patient who, after inhaling a bronchodilator to calm an asthma attack, inhaled a sharp metal pin inserted into the nozzle of the inhalation device. For eight years the patient presented episodes of recurrent pulmonary diseases treated with antibiotic therapy and the presence of a strangolingendobronchial body was never mentioned. Until it develops an abscess of the lung, bronchial fibroscopy has aloror objective the foreign body whose extraction necessitated a thoracotomy.</p> <p>This case illustrates the need to always re-cap the nozzle of the inhalation device after use. A simple gesture that will avoid this type of incident with sometimes dramatic complications requiring surgery in our patient's case.</p> <p>Keywords: Inhalation, Foreign Body, Dosed Aerosol, Case Report, Asthma</p>		

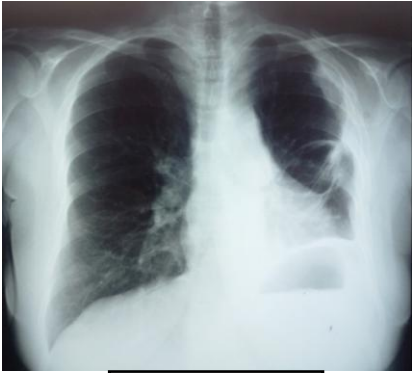INTRODUCTION

Asthmatics use aerosols so often that many precautions are neglected, such as closing the nozzle after use. We present the case of a 54-year-old teacher, known to be asthmatic. Who, while using a bronchodilator aerosol to relieve a mild asthma attack, accidentally inhaled a “cork board pin” that was locked in the device’s ventilation duct (1).

OBSERVATION

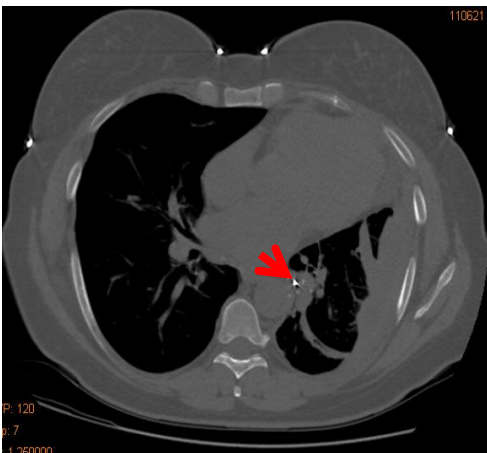
We report the observation of a 54-year-old teacher, followed for allergic asthma since the age of 14, well controlled under background treatment. She had an asthma attack that prompted the use of a salbutamol aerosol. Inhalation of a puff caused sudden worsening dyspnea that gave way after coughing. This symptomatology prompted a visit to the emergency room where the examination and clinical examination did not reveal the notion of accidental inhalation of the foreign body. During the past 09 years and for a period of time, the patient has had several episodes of left bronchopneumopathies (03) treated with antibiotic therapy. She attended the emergency department for frank infectious syndrome, cough, difficulty breathing and left chest pain. The blood count formula finds a hyperleucocytose GB: 13800/mm, a SV accelerates to 62 mmm, CRP raised to 46 mg/l. An x-ray (Fig. 1) and a chest CT scan (Fig. 2 and 3) revealed atelectasis of the left lower lobe and a foreign body of metallic density at the entrance to the lobar bronchus of the same lobe. During the interview, the patient remembered having had a penetration syndrome, nine years ago, following the accidental inhalation of an undefined foreign body that was trapped in the aeration duct of the aerosol left open which used during an asthma attack. The flexible bronchoscopy found a metallic foreign body whose end was sailled at the level of the orifice of the lower left lobar bronchus (Fig. 4). After the failure of the endoscopic extraction, the patient was assigned to the surgeon. The first surgical procedure was a posterolateral thoracotomy 5th left EIC and the extraction of the foreign body was performed by

bronchotomy. It was a cork board pin (Fig. 5)
The immediate course was satisfactory and the radiological control was normal.

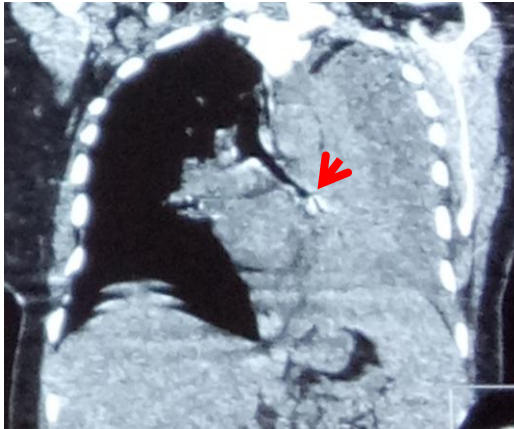


1

Fig 1: thoracic x-ray of the chest

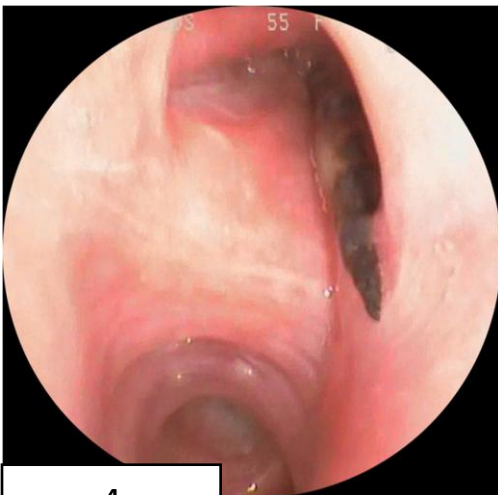

2



3

Fig 2, 3: Chest CT at admission



4

Fig 4: flexible bronchoscopy




Fig 5: extracted strangulated body

DISCUSSION

Inhalation of foreign body in the bronchial tree is most commonly found in young children (about 80-90% are children under 10 years old), according to the US series.

It is responsible for 7% of accidental deaths in children under four. One in three of these fatal accidents occurs among people over 85 years of age(2).

The association of an asthma attack and penetration syndrome is uncommon, but it does lead to a Conducive to the appearance of many complications such as pneumonia, lung abscess, bronchial perforation, hemoptysis, obstructive emphysema or severe sequelae such as bronchial stenosis, bronchitis bronchiectases, pneumothorax or pneumomeediastin(3).

All these factors are responsible for poor control of asthmatic disease, predisposing to episodes of asthma acute severe. This situation also poses a diagnostic problem since an endotracheobronchial foreign body may mimic a classic asthma attack(4).

The delay in diagnosis is often due to a lack of awareness of the time of the accident, especially among elderly people with significant cognitive impairment and difficult interrogation. Radiography of the thorax is a great diagnostic aid in case of radio opaque foreign body (6 to 20% of foreign body). In the case of radiopaque foreign body, images of obstructive emphysema, atelectasis, localized bronchodilation, pneumonia and exceptionally pneumothorax or pneumomediastin may be seen (5).

Treatment should be urgent especially in cases of complete airway obstruction and consists of removal of foreign body. The treatment of choice is endoscopic extraction and rigid bronchoscopy is often used(4).

Surgical extraction is indicated in the rare cases where foreign body is strongly impacted in the bronchial wall and cannot be removed by bronchoscopy or when it is too distal to be accessible to the endoscope (3).

In our observation, surgical extraction is indicated since the foreign body is strongly impacted in the bronchial wall and cannot be removed by bronchoscopy.

CONCLUSION

Inhalation of a foreign body enclosed in an aerosol is at least anecdotal, but can be responsible for serious consequences.

This case illustrates the need to always re-cap the spray tip after use and check the contents of its duct before administration.

We therefore recommend to all those who use aerosols much more attention at the time of their use and to us practitioners a good education of our patients.

REFERENCES

1. Boyd M, Chattergi A, Chiles C, Chin Jr R. Tracheobronchialforeign body aspiration in adults. South Med J 2009;102:171—4.
2. Tietjen PA, Kaner RJ, Quinn CE. Aspiration emergencies. Clin Chest Med 1994;15:117–35.

3. H. El Ouazzani et al. / Revue française d'allergologie 50 (2010) 634–636

4. Viot A, Babin E, Bequignon A, Moreau S, Vadillo M, Valdazo A. Corps étrangers intrabronchiques de l'enfant. Ann Otolaryngol Chir Cervicofac 2002;119:174–80.

5. S. Bacha*, S. Habibech , A. Chabbou Revue de Pneumologie clinique (2017) **73**, 109—114